



**DATE** PRESENTING CLINICAL SIGNS

12/16/21

History: Grade 3-4/6 murmur. Sedated for exam with butorphanol and midazolam.

**ECHOCARDIOGRAPHIC FINDINGS**

**PERFORMED BY:**

2D, M-mode, and Doppler study.

Potomac Mobile  
Veterinary  
Ultrasound

Left atrial size is normal. The mitral valve appears normal, though trace mitral regurgitation is present. There is mild left ventricular dilation. Left ventricular wall thickness is normal. Left ventricular systolic function is normal. The aorta and aortic appear normal, though there is mildly increased flow velocity in the ascending aorta. Right atrial and right ventricular dimensions are normal. The tricuspid valve leaflets are mildly thickened, and a mild jet of tricuspid regurgitation is present. TR velocity does not suggest the presence of pulmonary hypertension. The pulmonary artery and pulmonic valve are normal. No heartworms are visualized. No pericardial effusion or cardiac masses are seen.

**INTERPRETED BY**

Keith Blass, DVM,  
MS, DACVIM  
(Cardiology)

LA/Ao - 1.24

IVSd - 4.3 mm

LVPWd - 4.1 mm

LVIDd - 12.8 mm

LVIDs - 5.0 mm

FS - 60.9%

RA - 9.6 mm

LVOT - 3.15 m/s

RVOT - 0.65 m/s

TR - 2.56 m/s

**PATIENT**

Red Timmons

**SPECIES**

Feline

**ASSESSMENT/RECOMMENDATIONS**

**BREED**

Persian

This examination demonstrates mild regurgitation of blood across Red's tricuspid valve. The hemodynamic effects of the regurgitation also appear to be mild, as Red does not have secondary dilation of either of his right heart chambers. As such, Red's current risk for the development of clinical signs secondary to his regurgitation appears to be low.

**SEX**

M

Also seen in this exam is mildly increased flow velocity in Red's aorta, which could potentially be contributing to his murmur, though is unrelated to any dysfunction in this region.

**AGE**

2 y

No therapy is recommended based on this exam.

A recheck echocardiogram is recommended in 12 months, sooner if new clinical signs compatible with cardiac dysfunction develop.

**WEIGHT**

11 lb

**HOSPITAL NAME**

Vets and Pets AH

**REFERRING VET**

Dr. Jarrett



DATE

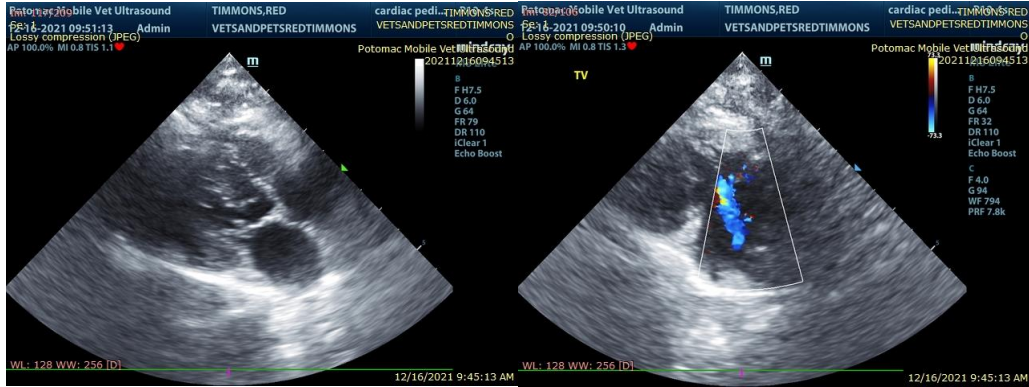
12/16/21

PERFORMED BY:

Potomac Mobile  
Veterinary  
Ultrasound

INTERPRETED BY

Keith Blass, DVM,  
MS, DACVIM  
(Cardiology)



The information and recommendations provided are based on the images presented by the referring veterinarian. No evaluation can be communicated regarding pathology that was not visible in the image/video clips provided.

Thank you for this referral. If the clinical or image interpretation does not parallel your findings or if I can be of any further assistance please contact me.

PATIENT

Red Timmons

Keith Blass, DVM, MS, DACVIM (Cardiology)  
KeithBlass@gmail.com  
631-804-5754

SPECIES

Feline

BREED

Persian

SEX

M

AGE

2 y

WEIGHT

11 lb

HOSPITAL NAME

Vets and Pets AH

REFERRING VET

Dr. Jarrett